

Case 2. Recurrent venous leg ulceration

Background

Mr B is a 76-year-old male with recurrent venous ulcerations over a period of 20 years after having developed deep vein thrombosis in both legs. He experiences nocturnal leg cramps. After a trauma, he developed a venous leg ulcer (VLU) on the right upper gaiter region that was being treated with a povidone-iodine-impregnated non-adherent dressing and an elasticated tubular bandage with two-way stretch. The wound was prone to recurrent infection and had undergone regular sharp debridement; the patient had also taken several courses of antibiotics.

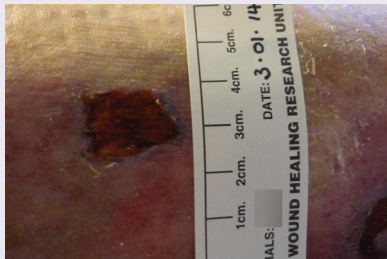


Figure 1. Initial assessment (3 Jan 2014)

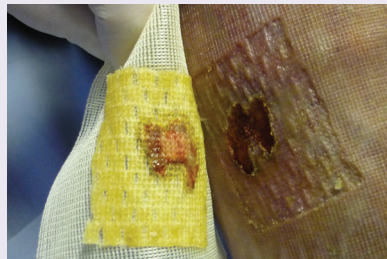


Figure 2. Week 4 (31 Jan 2014)

Treatment

Upon presentation, the two-month-old VLU measured 2.0cm x 1.5cm. The wound bed was described by the clinician as 'unhealthy', although the wound was not considered to be clinically infected. Due to the state of the wound bed, the decision was made to initiate treatment with ManukaDressIG MAX and a non-adherent polyester mesh secondary dressing, with twice-weekly dressing changes.

Week 1: After one week, the wound size was 2.4cm x 1.4cm, but the wound bed appeared healthier and there was an increase in granulation tissue to up to 25%. Due to this improvement, treatment with ManukaDressIG MAX was continued. The secondary dressing and changes remained the same.

Week 2: At the two-week assessment, the wound size was 1.5cm x 1.6cm (a 21% reduction), and the wound appeared clean, healthy and much improved. Granulation tissue comprised 100% of the wound bed. Due to the improvement and the patient's history of recurrent local and systemic infection, ManukaDressIG MAX was continued; a silicone secondary dressing and compression therapy were also initiated. Dressing changes were twice weekly.

Week 3: The wound size was 1.6cm x 1.6cm. There was minimal haemoserous exudate, with healthy granulation over 100% of the wound bed. Due to the high risk of re-infection and deterioration, the full dressing and treatment regimen was continued, with twice-weekly dressing changes.

Week 4: The wound measured 1.6cm x 1.6cm, a reduction of 15% from the initial size and 24% from its largest. Exudate was minimal and the wound bed was healthy, with no erythema present. Due to improvements and risk, ManukaDressIG MAX was recommended going forward, along with a non-adherent polyester mesh secondary dressing and compression therapy.

Discussion

The clinician reported that ManukaDressIG MAX was 'very easy to use and apply', although it could sometimes feel stiff at first. The patient reported no pain upon dressing change at any point, and the clinician was positive about the improvement in the wound bed and the VLU's progress towards wound healing.

Author: Ivins N

AUTHOR DETAILS

Bradbury S¹, Callaghan R², Ivins N³

1. Research nurse, wound healing, Institute for Translation, Innovation, Methodology and Engagement, Cardiff (UK) University School of Medicine
2. Tissue viability nurse, Worcester (UK) CCG nursing homes and Worcestershire Health and Care Trust
3. Clinical trials manager, wound healing, Institute for Translation, Innovation and Engagement, Cardiff (UK) University

Case 3. Sacral pressure ulcer with necrotic cover

Background

Ms W is a 72-year-old female with coarctation of the aorta, congestive cardiac failure and diabetes. After a stroke approximately 12 months ago, she was sent for rehabilitation and a home-living trial, which was unsuccessful. She was living in a nursing home and had very limited mobility; her overall health condition had deteriorated for a few weeks, leading to the development of a wound on her sacrum.

Treatment

The three-week-old wound comprised two areas, of 5.0cm x 4.0cm and 2.0cm x 3.0cm. It was assessed by a tissue viability nurse and judged to be a category III pressure ulcer, even though it was covered by 100% necrotic tissue, which made accurate grading difficult. The wound was leathery in feel, with slough present at the wound margins. Due to the presence of necrotic tissue, the need for prompt debridement and the overall fragility of the patient's skin, the decision was made to initiate treatment with ManukaDressIG MAX, with twice-weekly dressing changes. The treatment goal was to encourage debridement and provide an antimicrobial cover. A silicone foam adhesive was used as a secondary dressing. Use of a pressure-relieving mattress was initiated, as the patient was on bed rest.

Week 1: After one week, the wound size was the same, but reduction was not expected due to the initial necrotic tissue coverage. There was still slough at the wound edges, and necrotic cover exceeded 90%, but such tissue was softening and starting to come away at the edges. Due to this improvement and the clinician's judgement that the honey dressing needed time to penetrate the necrotic tissue, treatment with ManukaDressIG MAX was continued. The dressing regimen remained unchanged, and the mattress continued to be used for pressure redistribution.

Week 2: At the two-week assessment, the wound size was the same, but the slough at the margins was beginning to lift, revealing the beginnings of a pink wound margin. The area of necrotic tissue had begun to reduce (though was still about 90%). Exudate was now present, and the wound was sticky upon dressing removal. The clinician noted that the ManukaDressIG MAX was easy to apply, but is easier to apply if it is not very cold. Due to continued progress in terms of autolytic debridement, use of the primary dressing was continued. The dressing regimen remained unchanged, and the mattress continued to be used.

Week 3: The wound size remained unchanged, but was slightly deeper due to debridement of devitalised tissue, which resulted in several signs of progress. Necrotic tissue had reduced to between 25–50% of the wound area, and granulation tissue was present at the edges. Most tissue (50–75%) had become soft and sloughy. Exudate was controlled by the secondary dressing. Due to successful debridement, the dressing regimen was continued, along with the pressure-relieving mattress and turning of the patient every two hours.

Week 4: The wound size remained the same, as to be expected until completion of debridement. Necrotic tissue had reduced to almost 25%, slough to 25–50%, and granulation tissue covered up to 25% of the wound area. Due to continued improvement, the dressing and care regimens remained unchanged.

Discussion

The clinician reports that ManukaDressIG MAX was very good at debriding, easy to apply and comfortable for the patient, who reported no pain at any of the dressing changes. The dressing successfully debrided eschar that was judged to be really hard, and was continued for its autolytic debridement capability.

Author: Callaghan R

Note: Pictures were taken for this case, but images were of unsuitable quality for print.

ManukaDress

PRODUCTS FOR PRACTICE

made
easy

Introduction

With multiple antibiotic- and drug-resistant microbes emerging, wound clinicians are increasingly interested in alternative topical treatments to manage wound infection. Wound bed preparation – through ongoing debridement, exudate management and resolution of bacterial imbalance – is an essential component of managing infection and achieving wound healing (Schultz et al, 2003). One of the key reasons honey has come to the fore in modern wound care is that it provides an effective option for topical wound management due to its multiple modes of action. This Made Easy will explore these modes of action, explain how honeys differ, advise on use and application, summarise evidence, and present case studies of ManukaDress in practice.

Author: Bradbury S, Callaghan R, Ivins N

THE MANY ROLES OF HONEY

Honey provides a moist wound-healing environment, and is antimicrobial, de-odourising, anti-inflammatory/antioxidant and debriding – all of which address the key issues in wound bed preparation and bioburden management to promote healing in chronic wounds (Acton and Dunwoody, 2008; Seckam and Cooper, 2013). Honey's multimodal action lets it treat a variety of wounds that require addressing of multiple clinical factors, and eliminates the need for multiple products, making it a safe and easy treatment option. The three main considerations for optimal wound bed preparation are regular debridement to reduce devitalised tissue and encourage formation of healthy granulation tissue, restoration of bacterial imbalance and promotion of a moist wound-healing environment through exudate management (Schultz et al, 2003). Honey addresses these considerations with the following therapeutic properties:

Antimicrobial

Honey has high sugar and low water contents, which deprive bacteria of the water and suitable pH to support their growth (Molan, 2002; Gethin et al, 2008). Laboratory testing shows honey exhibits broad-spectrum antimicrobial activity against bacteria and fungi, including those most common causative organisms for wound infections: *Staphylococcus aureus*, including methicillin-resistant *S.aureus*, and *Streptococcus* (Cooper et al, 2002; Blair et al, 2009; Jenkins et al, 2011).

There is currently little evidence to suggest that microbial resistance or cytotoxicity to honey exist (Cooper et al, 2010),

although this is difficult to fully investigate, as the exact cellular mechanisms of honey within a wound are not fully known. Like silver, the most common alternative antimicrobial in current practice, honey is thought to have numerous target sites, which would require multiple bacterial mutations for resistance to develop. Some evidence suggests silver resistance does exist (Percival et al, 2005; Maillard, 2006); however, microbial resistance to honey has not been shown at present, and should be a consideration when choosing dressings.

Deodorising

Decomposition of necrotic wounds produces amino acids, which are metabolised by bacteria, producing ammonia and other odorous compounds (White and Molan, 2005). Honey provides bacteria with glucose as an alternative energy source to amino acids, resulting in the production of less odorous substances and thus reducing wound malodour (Molan, 2005). Honey further deodorises wounds by promoting the debridement of devitalised tissue and reducing bacterial bioburden.

Anti-inflammatory/antioxidant

Honey contains antioxidants, which are able to remove free radicals known to cause disruption in the inflammatory phase of wound healing (van den Berg et al, 2008). The anti-inflammatory effect of honey can also help prevent reformation of slough and devitalised tissue: decreasing exudate decreases the supply of fibrinogen, which is needed to form a clot that helps unhealthy tissue attach to the wound bed (Molan, 2009).

Moist wound healing

Honey creates a moist wound-healing environment due to its high sugar and low water contents. This composition exerts an osmotic action on the wound bed, drawing lymph from cells and fluid from the surrounding tissues. The results are a reduction in oedema and maceration to surrounding skin, and promotion of a moist wound-healing interface (Molan, 2005; Molan, 2009).

Debridement

It is assumed that the main means by which honey acts as a debriding agent is through facilitation of autolytic debridement by creating moist conditions, although there is some suggestion that the sugar content of honey is involved in activating proteases, which aid the debridement process (Molan, 2009). Honey may also promote autolytic debridement by causing an enzymatic action that activates plasmin, which disintegrates blood clots that bind necrotic tissue to the wound bed (Molan, 2005). International studies have indicated that a particular type of honey, manuka honey, is especially effective at preventing biofilm formation and at inhibiting established biofilms, although higher concentrations are required for the latter

(Alandejani et al, 2009; Cooper et al, 2011; Merckoll et al, 2009). Table 1 reviews honey's ability to debride, which is a vital method for managing microbial burden in wounds.

ARE ALL HONEYS THE SAME?

The biochemical and antimicrobial components of various honeys differ depending on factors such as floral source, climate and harvesting conditions (Cooper, 2012; Kwakman et al, 2011). Pesticides, pollutants and additives can also alter the characteristics of a honey, making it unsuitable for clinical use (Cooper, 2012). Results of experimental *in vitro* testing cannot be applied generically to all honeys due to their differing antimicrobial properties (Kwakman et al, 2011). Medical-grade honeys designed for clinical use are specially treated to destroy bacteria and contaminants, are from specific traceable sources, and have proven antimicrobial activity (Cooper, 2012). Clinicians should be aware that antimicrobial potencies of honey products vary, which affects the efficacy of the mode of action

in the wound environment (Molan, 2002; Acton and Dunwoody, 2008). For example, laboratory testing has demonstrated that honeys may differ in their osmotic potential, which may affect their efficiency at autolytic debridement (Medline, n.d.).

Laboratory testing indicates that honeys sourced from the *Leptospermum* species of plants, which includes manuka honey, are the honeys with superior antimicrobial efficacy (Cooper, 2008). Honeys available in supermarkets have relatively low antimicrobial activity compared to medical-grade honeys, carry increased risk of contamination with pathogenic organisms, and are not used in clinical practice (Cooper and Jenkins, 2009).

UNDERSTANDING MANUKADRESS

ManukaDress is composed of 100% pure manuka honey, which has been processed to medical-grade standards. Manuka honey:

- Assists wound cleansing and autolytic debridement due to its high osmolarity

Table 1: Clinical evidence for debridement capabilities of honey

Reference	Title	Study type	Main conclusions
Stephen-Haynes <i>Br J Community Nurs</i> 2004; 9(Suppl 6): 21-7	Evaluation of honey-impregnated tulle dressing in primary care	Case study (n=20)	<ul style="list-style-type: none"> ■ Medical-grade honey appears to be valuable for stimulating new tissue growth, moist wound healing, fluid handling and epithelialisation promotion
Subrahmanyam and Ugane <i>Indian J Surg</i> 2004; 66(2): 75-7	Honey dressing beneficial in treatment of Fournier's gangrene	Randomised trial (n=30) comparing honey dressing with Eusol	<ul style="list-style-type: none"> ■ In honey dressing patients (n=14), healthy granulation appeared in four patients in one week and in all patients within three weeks ■ Honey was more beneficial for treating Fournier's gangrene than Eusol
Gray and White <i>Wounds UK</i> 2005; 1(Suppl3): 32-5	Mesitran ointment case studies	Case study (n=30) of patients with venous and arterial leg ulcers, pressure ulcers, diabetic foot ulcers, pyoderma gangrenosum, and acute wounds	<ul style="list-style-type: none"> ■ Honey ointment showed positive results in terms of wound debridement ■ Controlled odour effectively ■ Deemed a 'good' financial comparison to alternative treatments
Okeniyi et al <i>J Altern Complement Med</i> 2005; 11(3): 511-3	Comparison of healing of incised abscess wounds with honey and Eusol dressing	Randomised controlled trial (n=32, with 43 pyomyositis abscesses) comparing honey and Eusol dressings	<ul style="list-style-type: none"> ■ Honey-treated wounds healed quicker and had significantly shorter hospital stays than Eusol-treated wounds ■ Researchers recommended honey for use on infected wounds
Gethin and Cowman <i>Int Wound J</i> 2008; 5(2): 185-94	The impact of Manuka honey dressings on the surface pH of chronic wounds	Randomised controlled trial (n=17, 20 ulcers) comparing manuka honey with a hydrogel for debridement of venous leg ulcers	<ul style="list-style-type: none"> ■ Manuka honey arm exhibited a statistically significant difference for increased incidence of healing at 12 weeks ■ Results felt to be clinically significant, as although both treatments led to a >50% slough reduction for 80% of the patients after four weeks, the honey arm displayed a greater percentage of slough removal. ■ Provides evidence honey products are successful debriding agents for VLU
Gethin GT and Cowman S <i>J Clin Nurs</i> 2009; 18(3): 466-74	Manuka honey vs. hydrogel – a prospective, open label, multicentre, randomised controlled trial to compare desloughing efficacy and healing outcomes in venous ulcers	Prospective, multicentre, open label randomised controlled trial (n=108 sloughy venous leg ulcers) that compared desloughing efficacy after four weeks and healing outcomes after 12 weeks of treatment with manuka honey or standard hydrogel therapy	<ul style="list-style-type: none"> ■ At week 4, mean percentage reduction in slough was 67% (manuka honey), 52.9% hydrogel ■ Median wound size reductions were 34% and 13%, respectively ■ At week 12, healing rates were 44% and 33%, respectively ■ Manuka honey may be considered effective by clinicians for use in sloughy venous ulcers; desloughing significantly improves healing outcomes
Molan PC <i>J Wound Technol</i> 2009;2(5): 12-7	Debridement of wounds with honey	Evidence review	<ul style="list-style-type: none"> ■ Honey removes attached slough, necrotic tissue and eschar by facilitating autolytic debridement ■ Autolytic debridement seems to occur due to osmotic effect, which encourages lymphatic flow to devitalised tissue and reduces bacterial burden ■ Using manuka honey in particular results in lower quantities of non-viable tissue
Evans and Mahoney <i>Wounds UK</i> 2013; 9(1): 30-36	Efficacy of medical-grade honey as an autolytic debridement agent	Case study (n=22)	<ul style="list-style-type: none"> ■ Honey dressings were effective at reducing necrotic tissue in 87% of patients and slough in 90% of patients ■ Honey dressings reduced odour and exudate

- Promotes a balanced, moist wound environment
- Reduces wound malodour
- Creates an acidic environment conducive to healing
- Is made from the nectar gathered from the manuka plant (*Leptospermum scoparium*) found in New Zealand.

ManukaDress (Box 1) is available as a gel (ManukaT) and a contact layer dressing (impregnated gauze; ManukaDressIG and ManukaDressIG Max).

When is ManukaDress indicated?

The gel and impregnated acetate gauze dressings can be used on:

- Trauma and surgical wounds
- Chronic ulcers (eg leg ulcers, diabetic foot and pressure ulcers)
- First and second degree burns
- Lacerations and abrasions.

The gel may be used on sinus or cavity wounds with low exudate levels. It can be used to debride necrotic tissue or top up dressings where the honey has been diluted by exudate. The dressings are indicated for shallow or granulating wounds with low to moderate levels of exudate and can be used to debride small areas of necrotic or sloughy tissue. For deeper wounds, the gel may be used in combination with the dressings.

Safety and tolerability

Medical honey should not be used in patients with known sensitivity to honey. Although concerns have been raised about its use in patients with diabetes, there is no evidence of increased blood sugar levels. However, it may be advisable to monitor blood sugar levels during use. Some patients may complain of a temporary increase in pain due to the osmotic action and/or low pH of the honey. If pain persists, discontinue use of the dressing and gently irrigate the wound with sterile saline solution.

How to apply and use ManukaDress

For superficial wounds, remove the dressing from the packaging, then remove the protective layers. Cut to size if necessary, place either side of the dressing on the wound, and cover with an appropriate secondary dressing. The gel, which can be used in combination with impregnated dressings, can be applied directly to the wound bed (approximately 3mm) in partial-thickness wounds or used to fill deeper wounds. Cover with an appropriate secondary dressing based on the tissue type and level of exudate.

Box 1. Defining ManukaDress

- **ManukaT** – Ideal for autolytic debridement of necrotic tissue. Suitable for difficult-to-dress wounds or wounds with low drainage.
- **ManukaIG** – Ideal for granulating or epithelialising tissue. Suitable for wounds with any drainage requirement when used with secondary dressing.
- **ManukaIG Max** – Ideal for debriding or de-sloughing necrotic or sloughy tissue. Due to the open cell construction, suitable for wounds with any drainage requirement when used with secondary dressing. Contains 200% more honey than ManukaIG.

The frequency of dressing changes will depend on how quickly the honey is diluted by exudate. At dressing change, wash off any honey residue using sterile saline solution.

Due to the lack of toxicity, manuka honey may be used for longer than two weeks. However, regular review should be performed and if there is no improvement at two weeks, consider an alternative approach. ManukaDress should be discontinued when treatment goals have been achieved.

SUMMARY

Overall, evidence promotes the role of honey in wound care as an effective and viable option for debridement and the maintenance of an optimal environment for wound healing. ManukaDress in particular has been shown to safely, effectively debride wounds that are not otherwise appropriate for undergoing sharp debridement (Table 2), along with promoting healing in a multimodal fashion.

REFERENCES

- Acton C, Dunwoody G (2008) The use of medical grade honey in clinical practice. *Br J Nurs* 17(20):S38–S44
- Alandejani T, Marsan J, Ferris W, et al (2009) Effectiveness of honey on *Staphylococcus aureus* and *Pseudomonas aeruginosa* biofilms. *Otolaryngol Head Neck Surg* 141(1):114–8
- Blair SE, Cokcetin NN, Harry EJ, Carter DA (2009) The unusual antimicrobial activity of medical-grade *Leptospermum* honey: antimicrobial spectrum, resistance and transcriptome analysis. *Eur J Clin Microbiol Infect Dis* 28(10):1199–208
- Cooper R (2008) Using honey to inhibit wound pathogens. *Nurs Times* 104(3):46–9
- Cooper R, Jenkins L (2009) A comparison between medical grade honey and table honeys in relation to antimicrobial efficacy. *Wounds* 21(2):1–9
- Cooper RA, Jenkins L, Henriques AFM, et al (2010) Absence of bacterial

Table 2. Debridement evidence for ManukaDress

Montoya L Poster presented at the Wound Ostomy and Continence Nurse Society's 45th Annual Conference, Seattle, USA: 30 June 2013	The use of leptospermum (manuka) honey for the moist wound management of wounds when sharp debridement is not an option or not preferred by the patient	Case study (n=12 patients whose wounds could not be debrided sharply; 10 completed study) assessing use of honey gel or dressing, depending on the wound, and appropriate secondary dressing	<ul style="list-style-type: none"> ■ Six patients achieved 100% reduction in visually assessed necrotic tissue (average 23 days, 39.1% weekly reduction rate) ■ Six patients achieved closure (average 43.3 days) ■ Average rate of necrotic tissue reduction in other patients was 82% (average 46 days) ■ Manuka honey dressings provided a moist wound environment, promoted autolytic debridement of necrotic tissue, and appropriately managed necrotic wounds
Wahab N Poster presented at the Clinical Symposium on Advances in Skin and Wound Care, Orlando, USA: 25 October 2013	Promotion of autolytic debridement by maintaining a moist wound healing environment via the use of medical grade honey in a long-term acute-care setting	Case study (n=15) of patients for whom sharp debridement was not an option, to assess autolytic debridement rates	<ul style="list-style-type: none"> ■ Average duration of wound care: 4.4 weeks ■ Average rate of reduction in necrotic tissue: 20% per week. Four patients achieved 100% reduction in visually assessed necrotic tissue ■ Average weekly wound size reduction: 17%; overall average wound size reduction: 50%

resistance to medical grade manuka honey. *Eur J Clin Microbiol Infect Dis* 29(10):1237–41

Cooper R, Jenkins L, Rowlands R (2011) Inhibition of biofilms through the use of manuka honey. *Wounds UK* 7(1):24–32

Cooper R, Gray D (2012) Is manuka honey a credible alternative to silver in wound care? *Wounds UK* 8(4):54–64

Du Toit DF, Page, BJ (2009) An *in vitro* evaluation of the cell toxicity of honey and silver dressings. *J Wound Care* 18(9):383–9

Gethin G, Cowman S (2008) Manuka honey vs. hydrogel – a prospective, open label, multicentre, randomised controlled trial to compare desloughing efficacy and healing outcomes in venous ulcers. *J Clin Nurs* 18(3):466–74

Gray D, White R (2005) Mesitran ointment case studies. *Wounds UK* 1(Suppl3):32–5

Jenkins R, Burton N, Cooper R (2011) Manuka honey inhibits cell division in methicillin-resistant *Staphylococcus aureus*. *J Antimicrob Chemother* 66(11):2536–42

Kwakman PHS, te Velde AA, de Boer L, et al (2011) Medical-grade honey enriched with antimicrobial peptides has enhanced activity against antibiotic-resistant pathogens. *Eur J Clin Microbiol Infect Dis* 30(2):251–7

Mailliard JY (2006) Focus on silver. Available at: <http://www.worldwidewounds.com/2006/may/Mailliard/Focus-On-Silver.html> (Accessed 03.02.2014)

Medline (n.d.) The Cochrane review on honey-based products: A considered view from Medline. DB1/ 76055357.1 Available at: <http://www.medline.com/media/mkt/pdf/Cochrane-summaries-on-debridement-10%20-9-13-FINAL.pdf>

Merckoll P, Jonassen TO, Vad ME, et al (2009) Bacteria, biofilm and honey: a study of the effects of honey on 'planktonic' and biofilm-embedded chronic wound bacteria. *Scand J Infect Dis* 41(5):341–7

Molan P (2002) Re-introducing honey in the management of wounds and ulcers – theory and practice. *Ostomy Wound Manage* 48(1):28–40

Molan P (2005) Mode of action. In: White R, Cooper R, Molan P (eds) *Honey: A modern wound management product*. Wounds UK, Aberdeen: 1–23

Molan PC (2009) Debridement of wounds with honey. *J Wound Technol* 5:12–17

Percival SL, Bowler PG, Russell D (2005) Bacterial resistance to silver in wound care. *J Hosp Infection* 60(1):1–7

Schultz GS, Sibbald RG, Falanga V, et al (2003) Wound bed preparation: a systematic approach to wound management. *Wound Repair Regen* 11(Supplement 1):S1–28

Seckam A, Cooper R (2013) Understanding how honey impacts on wounds: an update on recent research findings. *Wounds Int* 4(1):20–4

White R, Molan P (2005) A summary of published clinical research on honey in wound management. In: White R, Cooper R, Molan P (eds) *Honey: A modern wound management product*. Wounds UK, Aberdeen: 130–42

Case 1. Necrotic pressure ulcer on the heel

Background

Ms B, an 84-year-old female with hypothyroidism and arthritis, was mobile at her home with a Zimmer frame until she fell and broke her hip. After a surgical hip replacement, a necrotic pressure ulcer (PU) developed on the heel due to very restricted mobility. The wound was left to auto-debride until she was transferred to a nursing home, where she presented for treatment.

Treatment

The three-week-old wound measured 4.0cm x 3.0cm. The presence of 100% necrotic tissue rendered the wound ungradeable. The patient reported wound-related pain as 8 on a visual analogue scale of 1 to 10. As the PU was on the heel, Doppler assessment was done and confirmed adequate circulation. With no slough or granulation tissue present, ManukaDressIG was initiated to debride the necrotic tissue and enable development of granulation tissue. Secondary dressings comprised an absorbent pad and a bandage to keep the dressings in place. Dressing changes were scheduled for every three days or as needed.

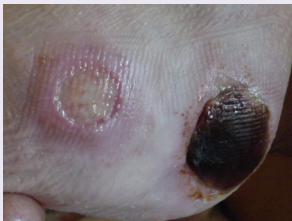


Figure 1. Week 1 (3 Jan 2014)

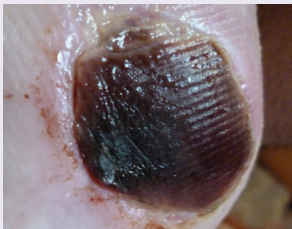

Figure 2. Week 2 (12 Jan 2014)

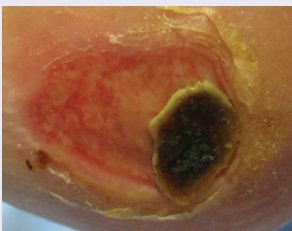


Figure 3. Week 4 (24 Jan 2014)

Week 1: After one week, the wound size was the same; reduction was not expected due to necrotic coverage. The clinician felt the dressing had softened the eschar, which was beginning to lift, but necrotic tissue coverage remained the same. The patient reported no pain before dressing change; she was given tramadol during dressing change and reported pain as a 3 out of 10. To debride the wound, the dressing choices and regimen remained the same.

Week 2: Wound size and necrotic coverage were the same. The patient's regular analgesia had been adjusted by the nursing home – analgesia was no longer being given for breakthrough pain, but on an as-needed basis – and she rated pain as a 4 before dressing change; with tramadol, she rated pain as a 5 during dressing change. To try to address the necrotic tissue, the primary dressing was changed to ManukaDressIG MAX. Secondary dressings and dressing-change frequency remained the same.

Week 3: The wound size remained unchanged, but the necrotic tissue had visibly softened and was lifting from the edges of the wound. The patient did not report pain before or during dressing change (without tramadol). ManukaDressIG MAX was continued; secondary dressings and change-frequency remained the same.

Week 4: Wound size remained the same; necrotic tissue had reduced to 50–75%, with a 'highly visible' difference in tissue. Exudate was present as the necrosis began lifting. Slough coverage was 25–50%. The patient did not report any pain before or during dressing changes. The dressing regimen and change schedule were prescribed again.

Discussion

The clinician reported initial slow debridement may have been due to delay in initiating use of ManukaDressIG MAX. The clinician remarked positively on the way the honey debrided the wound from the edges, leaving a core-like plug and allowing granulation tissue to grow in from the wound margin. Both the IG and IG MAX dressings were very easy to apply. They moulded well to the heel if warm, and cutting to shape resulted in a better fit.

Author: Callaghan R